Review

Received: 13.02.2019
Accepted: 14.03.2019

PRESERVATION OF SEXUAL FUNCTION IN RECTAL SURGERY

Mircea BEURAN
Carol Davila University of Medicine and Pharmacy, Bucharest
Emergency Hospital of Bucharest, Romania

„Keeping and renewing is almost as noble as creating"

Voltaire –" Philosophic dictionary"

Surgical anatomy of the rectum

Rectal surgery has been traditionally associated with sexual and urinary complications [1,2]. This conception has changed significantly over the past decades, with the addition of evidence that an anatomical dissection following embryological plans leads to similar oncological results but with a significant increase in quality of life. A decisive step was taken by Bill Heald, who introduced the total mesorectal excision for the treatment of rectal cancer in 1979 [3]. In 1991, Warren Enker detailed the preservation of autonomic nerves in the total excision of mesorectum [4]. Sympathetic innervation produces relaxation of smooth rectal muscles and muscle contraction of the internal anal sphincter (IAS). Parasympathetic stimulation produces contraction of rectal smooth muscle and relaxation of IAS. The external anal sphincter (EAS) is torn by the shy nerve and is volun-

Corresponding author: Prof. Univ. Dr. Mircea Beuran FACS "Carol Davila" University of Medicine and Pharmacy, Bucharest, Emergency Hospital of Bucharest, Romania, Calea Floreasca Nr. 8, Sector 1, Bucharest, Romania, E-mail: drbeuranmircea@yahoo.com

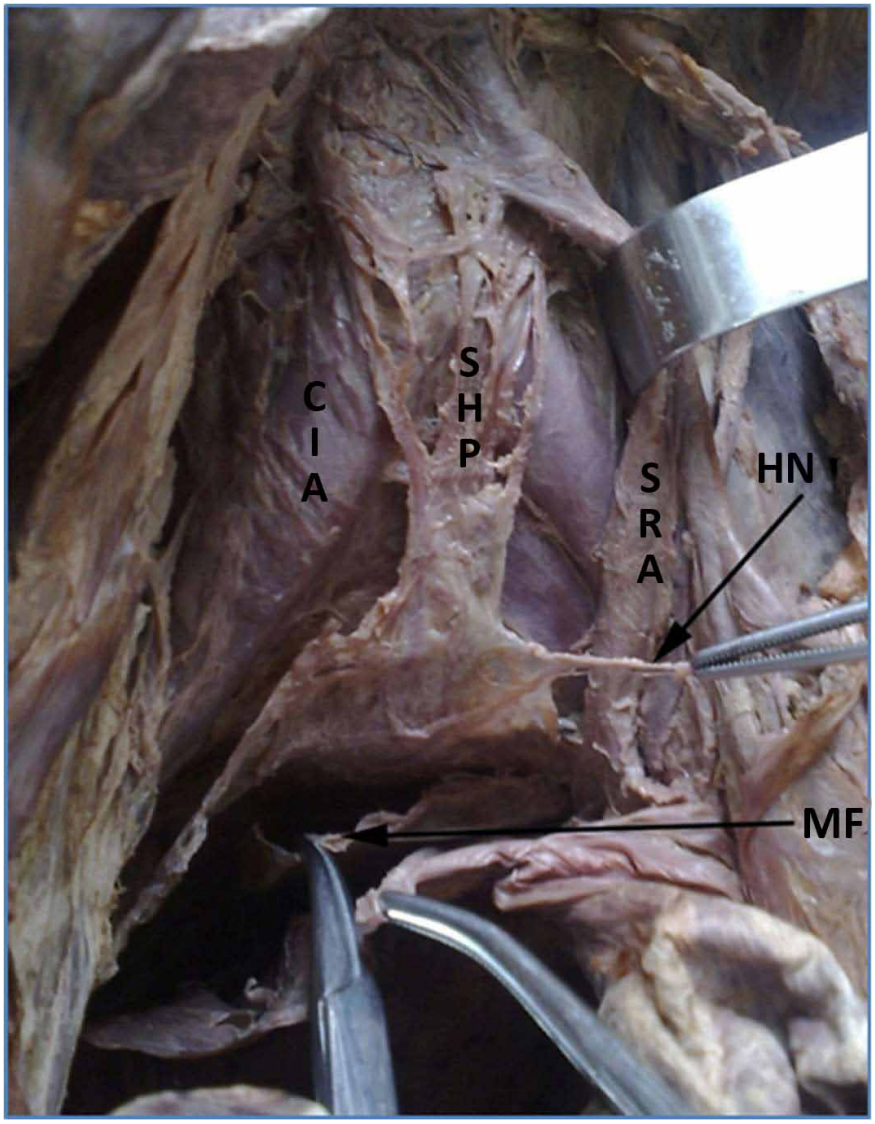

Figure 1:

Cadaver dissection. SHP – superior hypogastric plexus, HN – hypogastric nerve, MF – mesorectal fascia, SRA – superior rectal artery, CIA – common iliac artery (Picture from Emergency Hospital of Bucharest and Carol Davila University of Medicine and Pharmacy collection [1,2]).

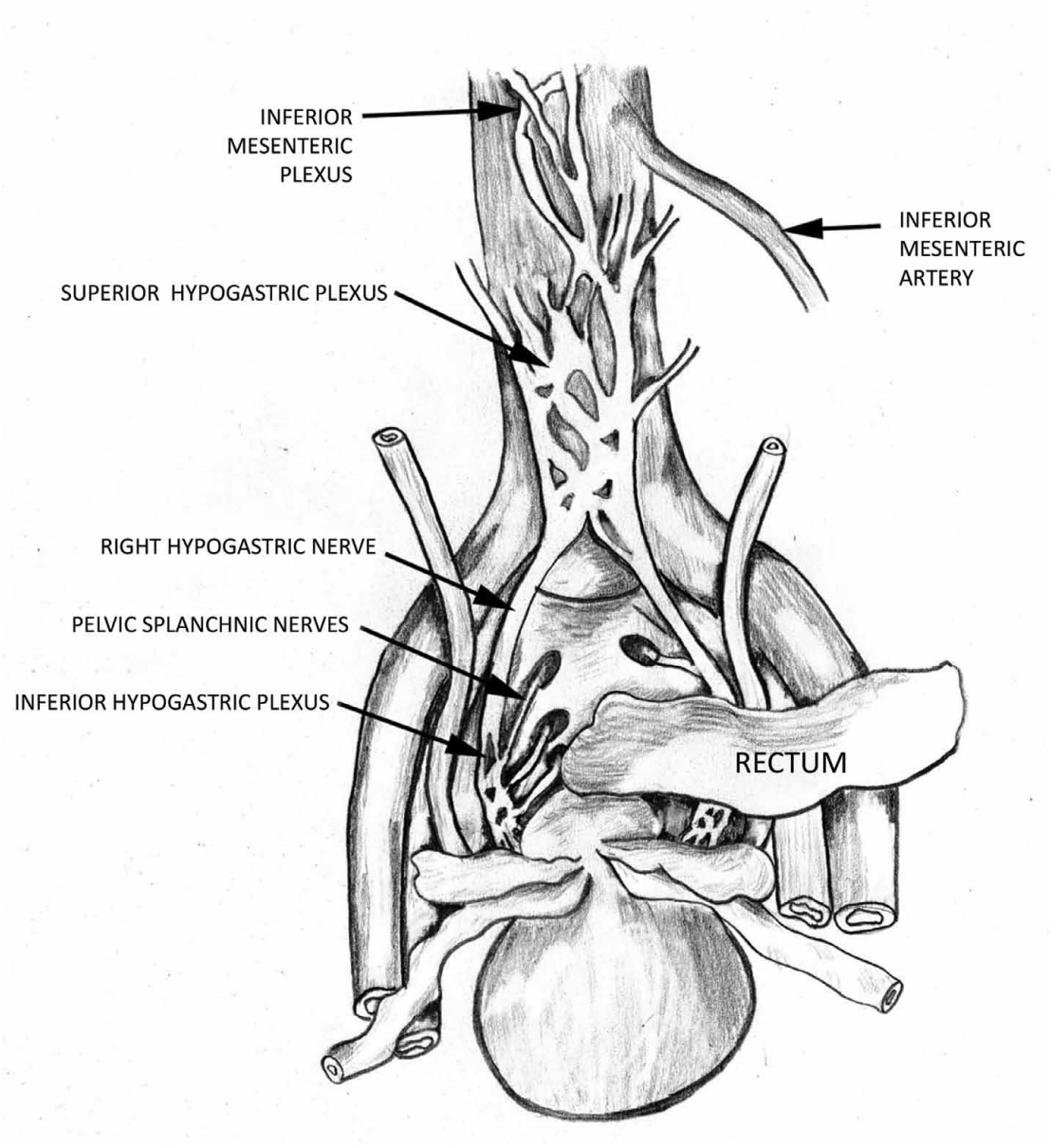

Figure 2:

Schematic representation of the pelvic vegetative nervous plexus (Image from the Emergency Hospital of Bucharest and Carol Davila University of Medicine and Pharmacy collections [1,2]).

tarily controlled. The nervous structures that innervate the pelvic organs can be organized into three structures: the superior hypogastric plexus, the hypogastric nerves and the lower hypogastric plexus [1,2]. The Superior Hypogastric Plexus (SHP) is a network of sympathetic nerve fibers, located anteriorly of the bifurcation of the aorta, sacral promontorium and between the common iliac arteries. This plexus receives sympathetic fibers from the aortic plexus (localized superiorly) and L3, L4 [1,2] (Fig.1).

This SHP can be damaged during lymphadenectomy, concurrently with dissection and ligation at the origin of the inferior mesenteric artery. SHP is continued to the inferior and lateral with 2 hypogastric nerves. Hypogastric nerves (HN) continue inferiorly SHP (Fig.2).

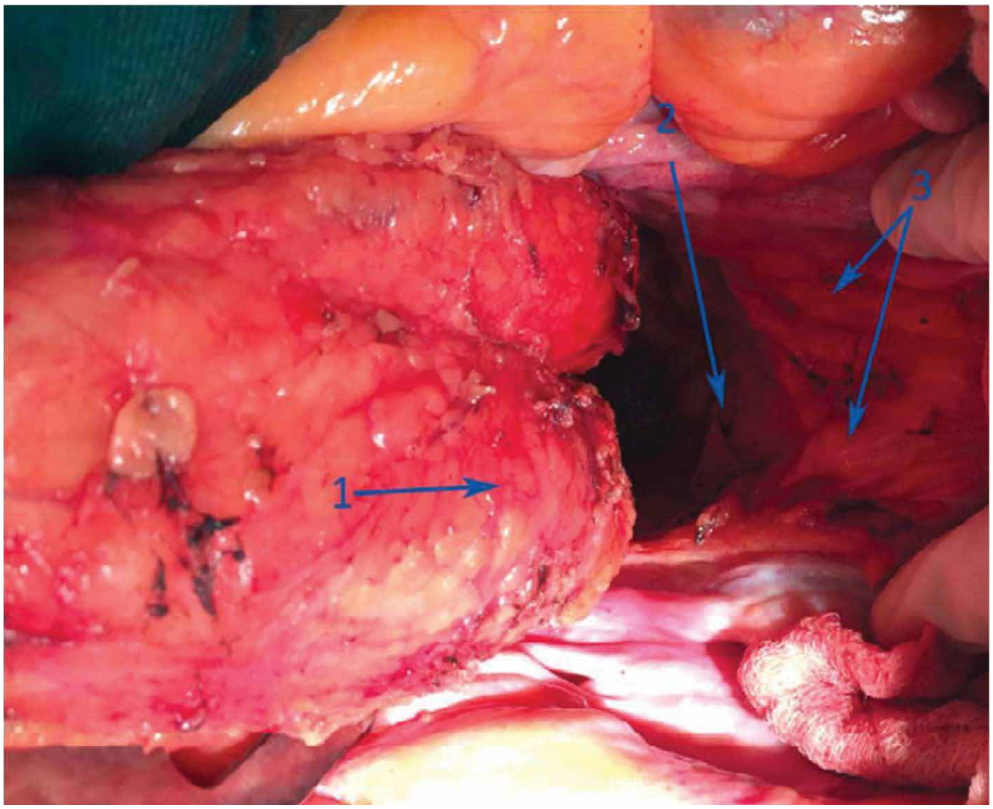

Figure 3:

Intraoperative aspect of the posterior dissection at the mesorectal fascia (1), anteriorly of the presacral fascia (2), during low anterior rectal resection. 3 – hypogastric nerves (Image from the Emergency Hospital of Bucharest and Carol Davila University of Medicine and Pharmacy collections [1,2]).

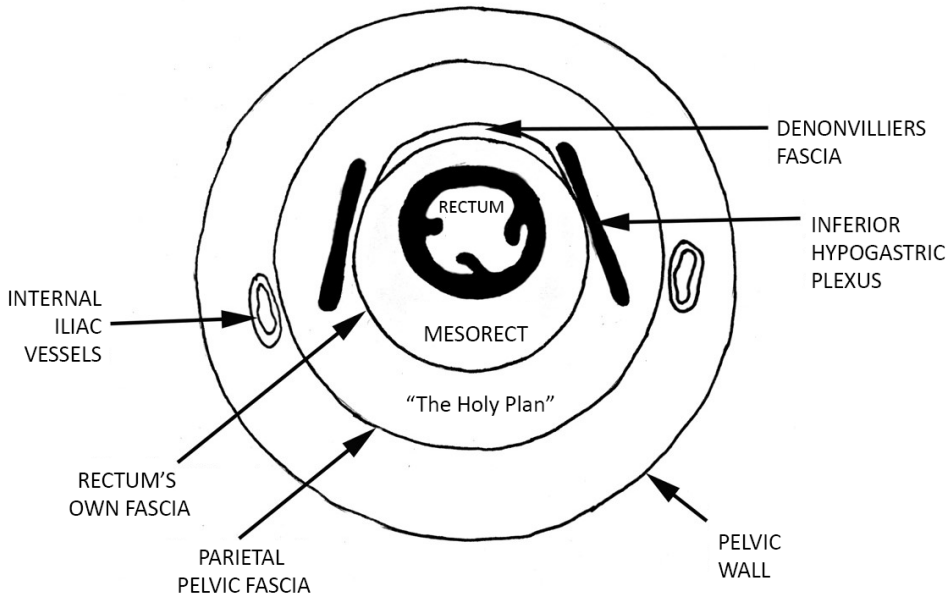

Figure 4:

Schematic representation of the spaces around the rectum. The pelvic fascia can be compared with the leaves of an onion (Image from Emergency Hospital of Bucharest and Carol Davila University of Medicine and Pharmacy collection) [1,2].

These nerves are formed predominantly from sympathetic fibers. At the sacral promontorium, the two hypogastric nerves are located 1 cm lateral of the median line. They continue inferiorly, parallel with the ureter, and are located 1-2 cm medial to it. Distally, at the level of the pelvic side walls, HN are joined with the pelvic splanchnic nerves (parasympathetic) to form the inferior hypogastric plexus. [1,2]. The hypogastric nerves are located external and postero-laterally by the rectum fascia – mesorectal fascia and anterior to the parietal endopelvic fascia (Fig.3). They are adherent to the rectum's own fascia and must be removed by visual control to the lateral, during the posterior dissection of the rectum. Inferior hypogastric plexus (IHP) is a nerve tissue blade oriented in a semi-planar plane between the rectum's own fascia an the parietal endopelvic fascia.

IHP is found on the antero-lateral face of the mesorectum, its middle being in the around the seminal vesicle. IHP is 4-5 cm long and is crossed by numerous vessels that run

to the rectum, bladder and internal genital organs. In men, IHP is located laterally from the seminal vesicles, prostate and bladder. In woman, IHP is located laterally from the cervix, vaginal fornix, bladder and sometimes extends into the broad ligaments of the uterus [1,2]. IHP is made up of sympathetic fibers that come from the hypogastric nerves and parasympathetic fibers that come from the pelvic splanchnic nerves or the erector nerves. Erector nerves originate at S2, S3, S4 levels. At the origin, erector nerves, are found in exterior of the parietal endopelvic fascia, but medial to internal iliac vessels (Fig.4). 3-4 cm anterior from their origin, posterior of the seminal vesicles, erector nerves perforate the parietal fascia from the lateral to the medial to end in the inferior hypogastric plexus. IHP continues to the anterior with branches that forms Walsh neurovascular fascicles.

These structures will innervate corpus cavernous and prostate. At the tip of the prostate, these structures approach the prostatic capsule at 5 and 7 o'clock. Ejaculatory function depends on the sympathetic component. Erection is produced by both parasympathetic (arteriolar vasodilatation) and sympathetic (inhibits vasoconstriction) [1,2]. Erection is under sacral parasympathetic control. Ejaculation is controlled by a complex mechanism driven primarily by lumbar sympathetic centers, and secondly by sacral parasympathetic centers. Sympathetic centers ensure contraction of the smooth muscles of the seminal vesicles, deferent duct, epididymis, as well as the bladder internal sphincter. Sacral parasympathetic centers also participate in this reflex by contracting perineal and urethral muscles and relaxing the bladder external sphincter [5].

Must be remembered that the left colon receives retrograde parasympathetic innervation from S2, S3 and S4. These fibers take the path through IHP, HN, SHP, inferior mesenteric plexus and with the branches of the inferior mesenteric artery reach the left colon. Some fibers go directly retroperitoneal to the left colon, without accompanying the branches of the inferior mesenteric [1,2].

Rectal resections for malignant disease

In modern rectal surgery, the complete excision of mesorectum is a desideratum for the malignant pathology of this segment of the digestive tract. In recent years, minimally invasive surgery has proven effective in curative treatment of rectal neoplasia, but open surgery remains the primary pathway for treating this pathology. The preservation of the pelvic nerves involved in pelvic statics, sphincter control and sexual function is also one of the main objectives [6]well established in the modern curative surgery of rectal cancer, needs further investigation, especially with regards to the preservation technic of the autonomous abdominopelvic innervation currently used to prevent or reduce the urogenital sequelae. The Authors offer a perspective study over the recovery of sexual activity in a homogeneous group of 32 male patients submitted, because of cancer, to restorative proctectomy, with anatomical preparation of the hypogastric and sacral plexus. The criteria for eligibility were the followings: male under 70 years of age, excision of the primary rectal cancer with coloanal or colo-rectal anastomosis performed at less than

5 cm from the anal verge, staging not more than T3N2M0, without previous RT or other pelvic operations and without protective enterostomy, nor local or systemic recurrences during the follow up period. The functional results obtained on the basis of a questionnaire, filled in quarterly by the patients as well as their partners for at least a year, three months after the operation were: lack of sexual disorders in 37.5%, reduction of the sexual activity (partial erection, lack of ejaculation, anorgasmy. A study published in 1999 by Prete et al. reported that sexual dysfunction occurred in 37.5% of cases at 3 months (incomplete erection, absence of ejaculation or anorgasmia), but at one year, 65.6% of the patients had normal sexual activity, in low anterior rectal resection with total mesorectum excision (TME) with preservation of autonomic nerves [6]well established in the modern curative surgery of rectal cancer, needs further investigation, especially with regards to the preservation technic of the autonomous abdominopelvic innervation currently used to prevent or reduce the urogenital sequelae. The Authors offer a perspective study over the recovery of sexual activity in a homogeneous group of 32 male patients submitted, because of cancer, to restorative proctectomy, with anatomical preparation of the hypogastric and sacral plexus. The criteria for eligibility were the followings: male under 70 years of age, excision of the primary rectal cancer with coloanal or colo-rectal anastomosis performed at less than 5 cm from the anal verge, staging not more than T3N2M0, without previous RT or other pelvic operations and without protective enterostomy, nor local or systemic recurrences during the follow up period. The functional results obtained on the basis of a questionnaire, filled in quarterly by the patients as well as their partners for at least a year, three months after the operation were: lack of sexual disorders in 37.5%, reduction of the sexual activity (partial erection, lack of ejaculation, anorgasmy.

In the literature, resection of rectal tumors with oncological limits is considered to be associated with a significant rate of sexual and urinary dysfunction. However, current surgery attempts to obtain both the excision within the oncological safety limits and the preservation of these functions. Procard et al. published in 2002 a study of 20 patients (13 men and 7 women) with rectal neoplasm with surgery per primam with complete excision of mesorectum, but with intraoperative identification and preservation of hypogastric and sacral splanchnic nerves. The tumors were staged according to the Astler-Coller classification, A1 and A2 - 3 cases, B1 – 7 cases, B2 – 2 cases, C2 – 1 case and D – 1 case. No postoperative urinary dysfunction or urodynamic changes were observed in any patient. 4 of the 7 women were sexually active preoperatively. Sexual activity and the ability to obtain orgasm have not been postoperatively altered, at one-year follow-up. 9 of the 13 men were potent preoperatively. Sexual activity and potency were not altered postoperatively in these men at one-year follow-up. Retrograde ejaculation was reported in one case. The authors also mentioned the decrease in intensity of erection in 4 patients at 3 months postoperatively, but with one-year remission [7].

However, it is known that cancer can spread along the nerve pathways. Based on this theorem, Maeda and colleagues conducted a prospective study in 2002 involving 50 patients. In 19 of these, preoperative, intrarectal, activated carbon particles were injected, so

intraoperatively the autonomic nerves were dissected from the adjacent connective tissue and microscopically analyzed; lymph nodes located along the axial and lateral drainage pathways were also microscopically analyzed. In 47 of the 50 cases, lymph nodes were found in connective tissue adjacent to the nerves. 2 of the patients showed positive nodules along the preaortic and presacral plexus, and one patient with positive lymph nodes at pelvic plexus were with unfavorable prognosis despite nerve resection. The authors conclude that in the case of tumors located cranially from the peritoneum reflection, lymphatic drainage is performed preferentially along the axial and lateral pathways, but in the case of those located lower than the reflection of peritoneum it disseminates along the nerve pathways, so in these cases, the complete excision of mesorectum with nerve preservation is not oncological safe [8].

In 2004, Tsunoda et al. conducted a retrospective study of 129 patients with rectal cancer who underwent two types of nerve-sparinginterventi-on. In 61 cases the superior hypogastric plexus an both hypogastric nerves were resected, and in 68 cases they were preserved. Pelvic plexus was preserved in all cases. Survival rates and local relapse rates between the two batches were compared. At 3 years, the relapse rate was 13.1% for the first batch and 10.3% for the second batch. The distance metastasis rate and the survival rate at 5 years were 23% and 61.6% respectively in patients with nerve resection and 16.2 % and 77.4% in those with nerve preservation. The authors conclusion was that there was no statistically significant difference between the two types of surgery [9].

In 2014, Ma G. et al. published an article on anatomical bases in low anterior rectal resection for the preservasion of autonomic nerves. They describe the pattern and distribution of pelvic autonomic nerves and their relationship with pelvic fascias in 12 men. Hypogastric nerves have a tract between the anterior sacral fascia and the inferior hypogastric plexus at the level of parietal fascia. Inferior hypogastric plexus crosses the Denonvilliers fascia fusion line with the parietal fascia at 10 and 2 a clock of the rectum and joins the urogenital vessels. The authors believe that the dissection safety plan should be chosen between the rectal fascia and the anterior sacral fascia in the posterior and lateral dissection of the rectum, with increased attention at 10 and 2 a clock of the rectum for the preservation of the neurovascular bundles, between the Denonvilliers and the rectal fascia [10].

Nerves cannot always be identified intraoperatively, which is why technology has been developed to help the surgeon. In 2004, an article was published in which a nerve stimulation device (CaverMap) was used to help identify intraoperative and confirm the preservation of these nerve structures. Thus, sexually active patients who underwent total excision of mesorectum were enrolled. During the dissection, the surgeon attempted to locate the hypogastric nerves in the corpus cavernous. CaverMap has been used to confirm their location and to facilitate their identification in uncertain cases. Upon completion of the proctectomy, the nerves were restimulated to confirm their preservation. 29 patients were included with an average age of 58 years old. In 26 cases, nerve identification was attempted, but only 73% (19) of cases could be achieved. In 6 out of 7, CaverMap device successfully identified. At the end of the proctectomy, the device was used for stimulation to confirm nerve preservation.

Although this device has been used successfully in the cases presented, an analysis is needed for larger batches of patients [11].

A meta-analysis published in 2011 by Moszkowicz an colleagues tried to draw attention to the key moments during dissection when these nerve structures may be injured. During the inferior mesenteric artery ligation and retro rectal dissection, the superior hypogastric plexus and/or the hypogastric nerves may be damaged. Antero-lateral dissection and division of the Denonvilliers fascia can injure the inferior hypogastric plexus and the efferent pathways. Perineal dissection can damage the pudendal nerves. The authors conclude that in most of the cases pelvic nerves can be preserved during the total excision of the mesorectum, but to obtain oncological resection, dissection must be as close as possible to the nerve structures [12].

With the introduction of neoadjuvant chemo-radiotherapy, obtaining a nerve preservation resection has become technically more difficult due to the local postradiotherapy treatment and more difficult dissection. Again, the technology helps the surgeon to achieve optimal results with minimal mortality and morbidity.

Laparoscopy an be used in the oncological surgery of the rectum, with a radical resection, as well as the preservation of pelvic plexus and nerves. Preservation of the pre-aortic plexus by ligation of the inferior mesenteric artery at 1-2 cm from aortic emergence with meticulous dissection of the mesosigmoid and mesorectum transition zone, identification of holy-plane and hypogastric nerves during the posterior and lateral dissection with nerve preservation up to the pelvic diaphragm with the identification of the lateral ligaments and inferior hypogastric plexus (10 and 2). The ligaments were split at the level of endopelvic fascia of the mesorectum to avoid injury of the inferior hypogastric plexus; lateral dissection at the edge of Denonvillier fascia, where the inferior hypogastric plexus is adjacent to the neurovascular bundles. Liang et al. included only patients with complete preservation of nerve structures and preoperative sphincter and sexual function. Sexual functions was analyzed in terms of potency and ejaculation in men, and from the point of view of vaginal lubrication, dyspareunia, sexual arousal and climax in the case of women. Patients were interviewed 6 months postoperatively (when reintegration of intestinal transit was performed) and at the end of convalescence. There were 98 patients, stage II – 44 and stage III – 54 (50 males and 48 females). 89 of these patients were operated laparoscopically with nerve preservation. The mean time for maintain urinary catheter was 7 days, with good urinary function in 71.6% of cases, satisfactorily in 23% and weak in 5.4%. Of the 17 patents with poor urinary function, in 8 of these patients, these conditions were transient. 32 males and 28 women with preoperative sexual activity completed the sexual function questionnaire. Ejaculation was good at 56.3%, satisfactorily in 18.7% and unsatisfactorily (retrograde ejaculation or impossibility of ejaculation) in 25% of patients. The potency was good in 62.5%, satisfactorily in 53.6% and unsatisfactorily in 21.9% of patients. For women, sexual function was good in 53.6%, satisfactorily in 14.3% and unsatisfactorily in 32.1%. The absence of vaginal lubrication was found in 46.6%, 39.3% dyspareunia, 28.6% lack of sexual arousal and in 32.1% anorgasmia [13]the aim of which is to determine if a laparoscopic approach can be

used in pelvic autonomic nerve-preserving surgery for patients with lower rectal cancer following chemoradiation therapy. Methods: Patients with T3 lower rectal cancer treated by preoperative chemoradiation were recruited and subjected to laparoscopic pelvic autonomic nerve-preserving surgery with total mesorectal excision and a sphincter-saving procedure. This study was performed with the approval of the ethics committee of National Taiwan University Hospital. Because the quality of a surgical trial is highly dependent on the skill of the surgeon with respect to the technique under study, it is imperative that a surgical trial only be implemented after the surgical technique has been judged to be mature. Before the start of this clinical trial, we gained a sound knowledge of surgical anatomy through conventional open surgery for rectal cancer and mastered the related laparoscopic skills from other sound and proven laparoscopic approaches, including right hemicolectomy, left hemicolectomy, among others. We determined that the learning curve for this surgical technique necessitated that colorectal surgeons carry out at least 20 such procedures. At this point we conducted this clinical trial. The details of the surgical procedures have been shown in the attached video. Briefly, the dissection commences at the pelvic promontory with exposure and preservation of the superior hypogastric plexus. The pre-aortic plexus and inferior mesenteric plexus are preserved by sparing the pre-aortic connective tissue and leaving a 1- to 2-cm-long stump of the inferior mesenteric artery in situ. Subsequently, the \"holy plane\" at the transition of the mesosigmoid to the mesorectum is meticulously dissected to progressively displace the hypogastric nerves dorsally and laterally and, therefore, preserving them. Following adequate dorsal and lateral dissection down to the floor of the pelvis, the so-called lateral ligament is reached at which the mesorectum appears to be adherent, anteriorly and laterally, to the inferior hypogastric plexus (at roughly 10:00-2:00 O'clock or within an angle of 60degrees about symphysis on both sides.

In 2013 Runkel and colleagues developed NOME – a nerve-oriented mesorectal excision consisting of identifying anatomical features for nerve preservation in laparoscopic rectal resection. They consider the pelvic nerves to be the benchmarks for standard dissection between the planes of the pelvic fasciae. The key points are: preparation for the splanchnic nerves at the median region of postero-lateral wall, hypogastric nerves superiorly at the lateral wall and urogenital bendlets antero-inferiorly at the lateral wall. Dissection of lateral ligaments is performed last. NOME was applied by the authors in 274 cases with partial or total excision of mesorectum (20.4% and 79.6% respectively). 42 men completed a sexual activity questionnaire. The conversion rate was 0.7%. The complete R0 resection was obtained in 90.1% and 95.3% respectively. The anastomosis fistula was found in 4.7% of the cases, and the mortality rate was 1.8%. Out of the 22 sexually active males interviewed, 81% of them maintained satisfactorily sexual activity in the postoperative period. In conclusion, NOME resections are an alternative treatment for rectal neoplasms, achieving morbidity and mortality compared to gold-standard technique [14]the hypogastric nerves at the upper sidewall, and the urogenital nerve branches (Walsh.

Robot surgery attempts to overcome certain limits of conventional laparoscopic sur-

gery. Andolfi et al. published a review of literature in 2018, where results from robotic surgery can be compared to laparoscopy from the point of view of oncology and short-term morbidity and mortality. The shortcomings of this type of intervention are high costs and operating time, but with a shorter learning curve. It has greater potential for rectal surgery due to the low conversion rate. Some studies also show a lower rate of anastomosis fistula, positive resection margins and better preservation of autonomous function [15].

Another study, published by Askild et al. in 2018, compares robotic surgery with laparoscopy from the point of view of postoperative period, short-term results and compliance with the Enhanced Recovery After Surgery (ERAS) protocol. The cohort included 224 patients who underwent a rectal resection for adenocarcinoma. 47 of the patients are part of the laparoscopy group, and 72 patients are in the robotic surgery group. For the robotic surgery the duration of hospitalization was lower (3 days vs. 7 days), had a lower conversion rate (11.1% vs. 34%), a lower postoperative complication rate (24% vs. 49%), but a longer operative time (5.8 hours compared with 4.5 hours). Compliance with the ERAS protocol was 81.1% for the robotic group and 83.4% for the laparoscopic group [16].

The robotic system attempts to overcome the shortcomings of open surgery, such as the narrow field of vision, given the localization of the rectum in a confined space, adhesion of the mesorectal fascia and the difficult identification of autonomic nerves in such a restrictive space. The development of this technology has led to overcoming these impediments with better results in preserving the nerve structures involved in genito-urinary functions by identifying the intraoperatively superior hypogastric plexus, hypogastric nerves, inferior hypogastric plexus and neurovascular bandlets [17,18]we successfully conducted transabdominal intersphincteric resection (ISR.

Luca F. and colleagues analyzed urinary and sexual function after robotic rectal resections with complete excision of mesorectum. They included 74 patients whos underwent such surgery. Sexual and urinary function was analyzed by pre-and-postoperative questionnaires. Sexual function at 1 postoperative month was considerably diminished with erectile dysfunction and decreased sexual satisfaction in men, and for women decreased libido and sexual satisfaction. Both functions, for both sexes, improved in the later period, so at 1 year postoperative the results were comparable with the ones before the surgery. From the point of view of urinary function, the degree of incontinence at one year after the intervention was unchanged for both sexes [19]74 patients undergoing fully robotic resection for rectal cancer were prospectively included in the study. Urinary and sexual dysfunctions affecting quality of life were assessed with specific self-administered questionnaires in all patients undergoing robotic total mesorectal excision (RTME.

Surgical resections for intestinal inflammatory diseases

Colonic inflammatory diseases, Chron disease and ulcerative hemorrhage recto-colitis (UHRC) are severe diseases of the digestive tract with common clinical, pathological and epidemiological affections, that affect young adults in particular, are incurable, require lifelong treatment, and sometimes multiple surgical interventions (intestinal resections, proctocolectomy, ileostomies, colectomy, etc.). The physiopathological mechanism of these diseases is the inflammation of the intestinal mucosa that can progress to ulceration, edema and bleeding. In UHRC, inflammation begins at the rectum where it can spread to the colon from close to closer affecting the entire large intestine. Unlike Chron's disease, where inflammation can affect any region of the digestive tract, with healthy areas between two regions affected by inflammation. Inflammatory diseases are associated with multiple gastrointestinal complications: toxic megacolon, hemorrhages, perforations, strictures, fistulas and perianal abscesses (all representing acute complications requiring surgical management); chronic inflammation increases the risk of gastro-intestinal neoplasia.

The treatment of inflammatory bowel disease is made up of two therapeutic steps: obtaining remission under appropriate medical treatment and preventing the disease being reactivated. Sometimes both medical and surgical treatment is needed. Surgical treatment of these diseases is encumbered a series of complications to which is added the inferior hypogastric plexus injury with consequences on urogenital functions.

An understanding of the anatomy and physiology of normal sexual function in men and women is essential to clarify more postoperative sexual disorders. Organic sexual dysfunction after proctocolectomy is more common in males than in females. The narrow conical pelvis makes frequent rectal mobilization more traumatic than in women, and nerves can be cut or elongated, resulting in a variety of postoperative sexual disorders. In addition, the increased incidence of male sexual dysfunction can be explained by the fact that in men only nerve disruption can completely eliminate erectile function. In women, sexual function can primarily be mediated by brain sexual centers and the impulses carried by pudendal nerves. Occasionally, men may have normal erectile function, but may experience retrograde ejaculation, as a postoperative complication or rectal excision. This is neurophysiological explained by the fact that the sympathetic nerves have been injured, the most likely location for this event being the disruption of the nerves at the sacral promontorium. At this level, sympathetic nerves are exposed, which are easily damaged during mobilization of the rectum. Thus retrograde ejaculation occurs, allowing sperm to go retrograde into the bladder rather than being expressed through the outside of the penis [20].

Rectal excision is associated with a risk of autonomous nervous system damage followed by sexual dysfunction (SD). The evolution of our understanding of the anatomy and physiology of sexual function, along with continuous improvement of surgery for both benign and malignant disease, led to decrease in the incidence of SD after

rectal surgery. A knowledge of postoperative SD risk is important for both the patient and the reference point for the audit of individual colorectal practice [21]physiology and surgical aspects of this topic has been researched through the Medline database. The more recently available data are reviewed in the context of the historical evolution of surgery for benign and malignant rectal disease.

RESULTS AND CONCLUSIONS

In the best hands, permanent impotence occurs in less than 2% of patients following restorative proctocolectomy and at a similarly low rate after proctocolectomy and ileostomy. Isolated ejaculatory dysfunction is also numerically a minor problem post operation for benign disease. Patient age is the most important predictor of SD after surgery for rectal cancer. The incidence of permanent impotence remains high (>40%).

A study from 2004 [21]physiology and surgical aspects of this topic has been researched through the Medline database. The more recently available data are reviewed in the context of the historical evolution of surgery for benign and malignant rectal disease. RESULTS AND CONCLUSIONS In the best hands, permanent impotence occurs in less than 2% of patients following restorative proctocolectomy and at a similarly low rate after proctocolectomy and ileostomy. Isolated ejaculatory dysfunction is also numerically a minor problem post operation for benign disease. Patient age is the most important predictor of SD after surgery for rectal cancer. The incidence of permanent impotence remains high (>40% shows that permanent impotence occurs in less than 2% of patients following restorative proctocolectomy and at a similar low rate after proctocolectomy and ileostomy. On the other hand, the age of the patient is the most important predictor of postoperative SD. The anatomical dissection of the pelvis with the preservation of said autonomic fibers leads to a low and predictable rate of sexual morbidity. Further research is needed to determine the effects of adjuvant therapy for rectal cancer on sexual function. The rectal dissection performed inside the mesorectum, close to the rectal muscle wall, in order to minimize the damage of pelvic sexual nerves to inflammatory bowel disease, can be performed with low impotence rate. Minor degrees of erectile disfunction may be more common than those currently recognized. I could not be demonstrated that a rectal wall significantly protects the patients from impotence compared to operation in the anatomical mesorectal plane. Age seems to be the most important risk factor for postoperative impotence.[22]

An ileo-anal anastomosis with the formation of a reservoir can alter sexuality and fertility in women. The laparoscopic approach seems to reduce infertility rates in women, however, the impact of manual versus mechanical anastomosis on sexuality and fertility has never been evaluated in UHRC patients. In this preliminary study, manual or mechanical technique did not influence the results of sexuality or fertility of patients with UHRC, but there was a tendency to improve female fertility and male erectile function in the case of manual anastomoses. The intestinal transit disorders have contributed to male and female sexual dysfunction after ileo-anal anastomotic surgery [23].

14 studies have been identified; six patients with colon inflammatory diseases registered in a national database or presented in a clinical setting, while eight studies evaluated sexual function after surgery for colonic inflammatory disease. Surgery does not seem to affect sexual function in most studies, except for a prospective study that reported a significant improvement in male but not female sexual function. In conclusion, sexual function among patients with colonic inflammatory disease may be impaired, but more studies are needed to develop appropriate tools and effective management strategies. [24].

There is an important concern about the effect of proctocolectomy on sexual function in patients with colon inflammatory disease. Little is known about gender differences. A 2011 study of sixty participants (41 men and 25 women) that were evaluated at baseline and 6 months after proctocolectomy or completion of proctocolectomy. 48 ileo-anal anastomosis with reservoir (31 males and 17 females) and 18 ileostomies (10 males and 8 females) were created. Both men and women reported improvement in general and quality of life after surgery, but only men have been shown to improve sexual function. Women reported an improved sexual desire without a general improvement in sexual function. The gender postoperative difference in sexual function was not important, despite similar improvements in quality of life [24–28] quality of life, bowel habits, and urinary symptoms, and were completed before and 6 months after surgery. RESULTS Sixty-six participants (41 men and 25 women.

Conclusions

In conclusion, regardless of the surgical approach used, either open, laparoscopic or robotic, the surgeon must perform an anatomical dissection that follows the embryological anatomical plans, preserving pelvic autonomous nerve structures to preserve the urinary, sphincter and sexual functions. To maximize the postoperative quality of our patients lives, we must respect both oncological principles and pelvic anatomical structures, a through dissection offering similar results in the rate of local recurrence and overall survival.

CONFLICT OF INTERESTS

The author declare that there is no conflict of interest

References:

1. Constantinescu N, Negoi I. Anatomia chirurgicală a rectului. In: Constantinescu N, editor. Anat. Chir. a pelvisului, 2018.
2. Beuran M, Negoi I. Rectum. Surg. Anat. Abdomen, Editura Academiei Române; 2018.
3. Heald R. Rectal Cancer in the 21st Century-radical Operations: anterior Resection and Abdominoperineal excision. In: Fischer J, editor. Mastery Surg., Lippincott Williams & Wilkins; 2007, p. 1542–55.
4. Havenga K, Enker WE. Autonomic nerve preserving total mesorectal excision. Surg Clin North Am 2002;82:1009–18.
5. D. Ion, R.V. Stoian, D.N. Păduraru, A. Bolocan MBÆ. Certitudini æi controverse privind conservarea elementelor nervoase în tehnica de excizie totală a mezorectului (ETM) n.d.
6. Prete F. [Neurovascular implications in total mesorectal excisions. A prospective study of sexual function after surgery for rectal cancer]. G Chir n.d.;17:393–8.
7. Pocard M, Zinzindohoue F, Haab F, Caplin S, Parc R, Tiret E. A prospective study of sexual and urinary function before and after total mesorectal excision with autonomic nerve preservation for rectal cancer. Surgery 2002;131:368–72.

8. Maeda K, Maruta M, Utsumi T, Hosoda Y, Horibe Y. Does perifascial rectal excision (i.e. TME) when combined with the autonomic nerve-sparing technique interfere with operative radicality? Colorectal Dis 2002;4:233–9.
9. Tsunoda A, Shibusawa M, Tanizaki H, Kusano M. Hypogastric nerve preservation does not increase local recurrence after surgical treatment of rectal carcinoma. Hepatogastroenterology n.d.;51:1354–7.
10. Ma G, Wang Y, Liang X. [Anatomical basis and main points of pelvic autonomic nerve preserving in proctectomy]. Zhonghua Wei Chang Wai Ke Za Zhi 2014;17:570–3.
11. da Silva GM, Zmora O, Börjesson L, Mizhari N, Daniel N, Khandwala F, et al. The Efficacy of a Nerve Stimulator (Cavermap®) to Enhance Autonomic Nerve Identification and Confirm Nerve Preservation During Total Mesorectal Excision. Dis Colon Rectum 2004;47:2032–8. doi:10.1007/s10350-004-0718-5.
12. Moszkowicz D, Alsaid B, Bessede T, Penna C, Nordlinger B, Benoît G, et al. Where does pelvic nerve injury occur during rectal surgery for cancer? Color Dis 2011;13:1326–34. doi:10.1111/j.1463-1318.2010.02384.x.
13. Liang JT, Lai HS, Lee PH. Laparoscopic pelvic autonomic nerve-preserving surgery for patients with lower rectal cancer after chemoradiation therapy. Ann Surg Oncol 2007;14:1285–7. doi:10.1245/s10434-006-9052-6.
14. Runkel N, Reiser H. Nerve-oriented mesorectal excision (NOME): autonomic nerves as landmarks for laparoscopic rectal resection. Int J Colorectal Dis 2013;28:1367–75. doi:10.1007/s00384-013-1705-x.
15. [15] Andolfi C, Umanskiy K. Appraisal and Current Considerations of Robotics in Colon and Rectal Surgery. J Laparoendosc Adv Surg Tech 2018:lap.2018.0571. doi:10.1089/lap.2018.0571.
16. Asklid D, Gerjy R, Hjern F, Pekkari K, Gustafsson UO. Robotic *vs* laparoscopic rectal tumour surgery: a cohort study. Color Dis 2018;21:codi.14475. doi:10.1111/codi.14475.
17. Park SY, Choi G-S, Park JS, Kim HJ, Choi W-H, Ryuk JP. Robotic-assisted Transabdominal Intersphincteric Resection. Surg Laparosc Endosc Percutan Tech 2013;23:e5–10. doi:10.1097/SLE.0b013e318275b27a.
18. Kim NK, Kim YW, Cho MS. Total mesorectal excision for rectal cancer with emphasis on pelvic autonomic nerve preservation: Expert technical tips for robotic surgery. Surg Oncol 2015;24:172–80. doi:10.1016/j.suronc.2015.06.012.
19. Luca F, Valvo M, Ghezzi TL, Zuccaro M, Cenciarelli S, Trovato C, et al. Impact of Robotic Surgery on Sexual and Urinary Functions After Fully Robotic Nerve-Sparing Total Mesorectal Excision for Rectal Cancer. Ann Surg 2013;257:672–8. doi:10.1097/SLA.0b013e318269d03b.
20. Bauer JJ, Gelernt IM, Salky B, Kreel I. Sexual dysfunction following proctocolectomy for benign disease of the colon and rectum. Ann Surg 1983;197:363–7.
21. Keating JP. Sexual function after rectal excision. ANZ J Surg 2004;74:248–59. doi:10.1111/j.1445-2197.2004.02954.x.
22. Lindsey I, George BD, Kettlewell MG, Mortensen NJ. Impotence after mesorectal and close rectal dissection for inflammatory bowel disease. Dis Colon Rectum 2001;44:831–5.
23. Harnoy Y, Desfourneaux V, Bouguen G, Rayar M, Meunier B, Siproudhis L, et al. Sexuality and fertility outcomes after hand sewn versus stapled ileal pouch anal anastomosis for ulcerative colitis. J Surg Res 2016;200:66–72. doi:10.1016/j.jss.2015.06.054.
24. Mantzouranis G, Fafliora E, Glanztounis G, Christodoulou DK, Katsanos KH. Inflammatory Bowel Disease and Sexual Function in Male and Female Patients: An Update on Evidence in the Past Ten Years. J Crohn's Colitis 2015;9:1160–8. doi:10.1093/ecco-jcc/jjv140.
25. Wang JY, Hart SL, Wilkowski KSY, Lee JW, Delmotte EC, del Rosario KM, et al. Gender-specific differences in pelvic organ function after proctectomy for inflammatory bowel disease. Dis Colon Rectum 2011;54:66–76. doi:10.1007/DCR.0b013e3181fd48d2.
26. [26] Memon MA, Yunus RM, Memon B, Awaiz A, Khan S. A Meta-Analysis and Systematic Review of Perioperative Outcomes of Laparoscopic-assisted Rectal Resection (LARR) Versus Open Rectal Resection (ORR) for Carcinoma. Surg Laparosc Endosc Percutan Tech 2018;28:337–48. doi:10.1097/SLE.0000000000000589.
27. Lin Z, Jiang Z-L, Chen D-Y, Chen M-F, Chen L-H, Zhou P, et al. Short- and long-term outcomes of laparoscopic versus open surgery for rectal cancer. Medicine (Baltimore) 2018;97:e13704. doi:10.1097/MD.0000000000013704.
28. Truong A, Lopez N, Fleshner P, Zaghiyan K. Preservation of Pathologic Outcomes in Robotic versus Open Resection for Rectal Cancer: Can the Robot Fill the Minimally Invasive Gap? Am Surg 2018;84:1876–81.